


Contents lists available at [ScienceDirect](http://www.sciencedirect.com)

# Taiwanese Journal of Obstetrics & Gynecology

journal homepage: [www.tjog-online.com](http://www.tjog-online.com)

## Original Article

### A mixture of St. John's wort and sea buckthorn oils regresses endometriotic implants and affects the levels of inflammatory mediators in peritoneal fluid of the rat: A surgically induced endometriosis model

Mert İlhan <sup>a</sup>, İpek Süntar <sup>a</sup>, Mürşide Ayşe Demirel <sup>b</sup>, Erdem Yeşilada <sup>c</sup>, Hikmet Keleş <sup>d</sup>, Esra Küpeli Akkol <sup>a,\*</sup>

<sup>a</sup> Department of Pharmacognosy, Faculty of Pharmacy, Gazi University, Etiler, Ankara, Turkey

<sup>b</sup> Laboratory Animals Breeding and Experimental Researches Center, Faculty of Pharmacy, Gazi University, Etiler, Ankara, Turkey

<sup>c</sup> Department of Pharmacognosy, Faculty of Pharmacy, Yeditepe University, Atasehir, Istanbul, Turkey

<sup>d</sup> Department of Pathology, Faculty of Veterinary Medicine, Afyon Kocatepe University, Afyonkarahisar, Turkey



## ARTICLE INFO

### Article history:

Accepted 27 January 2015

### Keywords:

cytokine  
experimental endometriosis model  
*Hippophae rhamnoides* (sea buckthorn)  
*Hypericum perforatum* (St. John's wort)

## ABSTRACT

**Objective:** Sea buckthorn (*Hippophae rhamnoides* L.) and St. John's wort (*Hypericum perforatum* L.) are used as an emmenagog and for the treatment of other gynecological disorders including uterus inflammation and endometriosis. The aim of the present study is to investigate the potential of a mixture of sea buckthorn and St. John's wort oils (HrHp oil) in the treatment of endometriosis.

**Materials and Methods:** The activity was assessed in surgically induced endometriosis in rats. A 15-mm piece of endometrium was sutured into the abdominal wall. Twenty-eight days later, a second laparotomy was performed to calculate the endometrial foci areas and to score intra-abdominal adhesions. The rats were treated with either vehicle, HrHp oil formulation, or the reference (buserelin acetate). At the end of the experiment all rats were sacrificed and endometriotic foci areas and intra-abdominal adhesions were re-evaluated. The tissue sections were analyzed histopathologically. Peritoneal fluids of the experimental animals were collected in order to detect the levels of tumor necrosis factor- $\alpha$ , vascular endothelial growth factor, and interleukin-6, which might be involved in the etiology of endometriosis.

**Results:** In the HrHp oil-treated group, the volumes of endometriotic implants were found to be significantly decreased (from 50.8 mm<sup>3</sup> to 18.6 mm<sup>3</sup>,  $p < 0.001$ ) without any adhesion ( $0.0 \pm 0.0$ ,  $p < 0.001$ ) when compared to the control group ( $3.1 \pm 0.9$ ). The levels of tumor necrosis factor- $\alpha$  decreased from  $7.02 \pm 1.33$  pg/mL to  $4.78 \pm 1.02$  pg/mL ( $p < 0.01$ ); vascular endothelial growth factor from  $17.39 \pm 8.52$  pg/mL to  $9.67 \pm 5.04$  pg/mL ( $p < 0.01$ ); and interleukin-6 from  $50.95 \pm 22.84$  pg/mL to  $29.11 \pm 7.45$  pg/mL ( $p < 0.01$ ), respectively, after HrHp oil treatment.

**Conclusion:** HrHp oil may be a promising alternative for the treatment of endometriosis.

Copyright © 2016, Taiwan Association of Obstetrics & Gynecology. Published by Elsevier Taiwan LLC. This is an open access article under the CC BY-NC-ND license (<http://creativecommons.org/licenses/by-nc-nd/4.0/>).

## Introduction

Endometriosis is a common disease among the women, characterized by the growth of endometrial-like tissue outside the uterine cavity. It is a chronic condition in which ectopic

endometriotic implants are found on the peritoneal surface or within the ovary [1]. Secondary dysmenorrhea is one of the most common symptoms in women with endometriosis. During the pre-menstrual periods, pain is frequently accompanied by dyspareunia, dysuria, or dyschezia [2]. Although recent evidence suggest epigenetic aberrations and heritable changes in the genome as the main factors involved, the etiology of endometriosis is still poorly understood. However, estrogen levels are known to be increased in the case of endometriosis. Many of the treatment procedures of endometriosis rely on the decrease in the estradiol

\* Corresponding author. Department of Pharmacognosy, Faculty of Pharmacy, Gazi University, Etiler, 06330, Ankara, Turkey.  
E-mail address: [esrak@gazi.edu.tr](mailto:esrak@gazi.edu.tr) (E. Küpeli Akkol).

level, due to the fact that high estradiol levels trigger the development of endometriotic lesions. Among the therapy protocols suggested for the treatment of endometriosis in current medical practice, gonadotropin-releasing hormone analogues such as buserelin acetate, which was used as a reference drug in the present study, is the most preferred. However, due to the side effects induced by such gonadotropin-releasing hormone analogues in clinical practice, search for the invention of new drug candidates are warranted [3,4]. Difficulty in the long-term management of endometriosis symptoms and unpredictability of treatment outcome necessitate research into other treatment modalities, including herbal medicines [5].

Sea buckthorn (*Hippophae rhamnoides* L.; Elaeagnaceae) fruit is a rich source of vitamins C and E, carotenoids, flavonoids, anthocyanidins, organic acids, amino acids, sterols, triterpenols, and isoprenols [6–8]. The fixed oil obtained from fruit pulps was reported to contain carotenoids as well as palmitic, palmitoleic, and oleic acids, while the seed oil was composed of linoleic, linolenic, and oleic acids, as the major components [9]. This oil has traditionally been used to improve the blood circulation and for the treatment of dermatological problems including wounds, gastritis, peptic ulcers, uterine erosion, and inflammatory disorders of genital organs [8,10].

The flowering aerial part of St John's wort (*Hypericum perforatum* L.; Clusiaceae) is an important and worldwide popular herbal remedy due to its diverse biological and chemical perspectives. In Turkish folk medicine, it has been recorded as a remedy for neuralgia, heart diseases, gastritis, peptic ulcers, diabetes mellitus, urogenital inflammations, and hemorrhoids [11,12]. A reference survey has also revealed that various types of preparations to possess a broad spectrum of antimicrobial, antidepressant, diuretic, and emmenogog activities [13,14]. In the expert report on *H. perforatum* herb, which was prepared and published by Committee on Herbal Medicinal Products, the traditional use of *H. perforatum* against endocrine disorders including endometritis has been documented [15]. The olive oil macerate of the flowering aerial parts is a well-known home remedy for cuts and burns externally, and peptic ulcers internally [11,12]. The macerate is prepared by mixing the dried flowering parts with olive oil and keeping this mixture for about 1 month in direct sunlight. Through *in vivo* bioassay-guided processing naphthodianthrones (hypericin) and flavonoids were found to be the compounds responsible for the wound healing activity of *H. perforatum* oil [16].

In the present study, the efficacy of a combined preparation of *H. rhamnoides* and *H. perforatum* oils (HrHp oil) on the surgically-induced endometriosis model in rats was investigated.

## Material and methods

### Materials

The oil of *H. rhamnoides* L. was obtained from whole berries including pulps and seeds and standardized on its fatty acid content (> 85%) [AC320241]. Olive oil macerate of *H. perforatum* L. was obtained from the flowering aerial parts. Both certificated extracts were purchased from Naturex (Avignon, France) and they were combined at a ratio of 90 to 60, respectively. The mixture formulation was encoded as HrHp oil. The authors acknowledge Biota Co. (Istanbul, Turkey) for kindly providing the oil extracts.

### Animals

In the present study, 6-week-old female, nonpregnant, Sprague-Dawley rats (200–250 g) purchased from Laboratory

Experimental Animals, Kobay, Turkey were used. The animals were housed in polysulfone cages at 21–24°C, 40–45% humidity, and light-controlled (12 hours light/12 hours dark) conditions at Laboratory Animals Breeding and Experimental Research Center, Gazi University (Ankara, Turkey) and maintained on standard pellet diet and water *ad libitum* throughout the experiment. The animals were treated in accordance with the directions of Guide for the Care and Use of Laboratory Animals, and the present study was approved by the Experimental Animal Ethics Committee of Gazi University (G.U.ET-14.068). By daily assessment of vaginal cytology, the estrous cycle was followed. Rats exhibiting regular 4–5 day estrous cycles were selected and grouped for experimentation.

### The procedure of the surgically induced rat endometriosis model

In the present study, the endometriosis model which was previously described by Vernon and Wilson [17], was performed. The anesthetic drugs medetomidin (0.5 mg/kg; Domitor; Orion Pharmos, Pharmaceutical Pfizer Animal Health, Espoo, Finland) and ketamine hydrochloride 10% (100 mg/kg; Ketazol; Interhas, Ankara, Turkey) were intramuscularly administered to the rats at the proestrous stage. The rats were placed in the supine position and the abdomen was disinfected with iodine. A midline incision of 3 cm was created and the right uterine cornu was resected. A 1.5-cm piece of the tissue was cut and longitudinally opened. The endometrium layer was separated from myometrium and sutured with USP 4/0 polyglactin (Lactasorb PGLA; Orhan Boz, Ankara, Turkey) into the abdominal wall of the same rat. The muscle layers of the abdomen were closed with USP 3/0 polyglactin (Lactasorb PGLA; Orhan Boz) [18]. Twenty-eight days after the first operation, a second laparotomy was performed to evaluate the volumes of endometriotic implants and to score the adhesions. The volumes were calculated by measuring the size of the length, width, height by a micrometer. For the calculation of the ellipsoid volume, the equation ( $\pi/6 \times \text{length} \times \text{width} \times \text{height}$ ) was used [19]. Intra-abdominal adhesions were scored according to the Blauer scoring system [20]: 0: no adhesion; 1: thin adhesions; 2: thick adhesion in one area; 3: widespread thick adhesions; 4: adhesions of the internal organs to the abdominal wall. The abdomen was then closed.

### Treatment procedure

Rats were randomly divided into three groups of six rats each. Three days after the second laparotomy 0.5% CMC (control group) or HrHp oil (2 mL/rat) was applied by gastric gavage daily throughout 4 weeks. The reference drug, buserelin acetate (20 mg/rat), was subcutaneously injected once a week during the treatment period.

### Termination of the experimental phase

At the end of the administration period, rats were sacrificed, and endometriotic foci areas and intra-abdominal adhesions were again evaluated and compared with previous calculations.

### Techniques for histopathological investigation

Tissue samples from implantation regions were taken for histopathological examination after necropsy protocol. The samples were fixed in 10% neutral formal saline, embedded in paraffin, cut into 5- $\mu\text{m}$  sections on a microtome, stained with hematoxylin-eosin and examined under a light microscope (Olympus CX41 attached to a Kameram Digital Image Analysis System) [21].

### Detection of cytokine levels

In order to detect the levels of tumor necrosis factor- $\alpha$  (TNF- $\alpha$ ), vascular endothelial growth factor (VEGF), and interleukin-6 (IL-6) levels, the peritoneal fluid of each animal were collected. TNF- $\alpha$ , IL-6 (Bio Source International, Nivelles, Belgium; catalog numbers MBS453189 and MBS701221) and VEGF (eBioscience, Vienna, Austria; catalog number: BMS626/2) were quantitatively assessed using commercially available enzyme-linked immunosorbent assay kits according to the manufacturer's instructions. Experimental results recorded during pre- and post-treatment were compared and statistically evaluated.

### Statistical analysis

The results are expressed as the mean  $\pm$  standard deviation. To determine the significance of differences between groups, Dunnett's test; and to compare two groups Student *t* test was used [22].

### Results

In the present study, the activity of HrHp oil was assessed using a surgically-induced endometriosis model in rats. The volumes of endometriotic implants were measured before and after the treatment with vehicle, HrHp oil or reference drug (buserelin acetate). The second laparotomy revealed that the implants were in vascularized and cystic formation before the treatment procedure (Figure 1). After treatment with reference drug and HrHp oil, volumes of the implants were determined to be significantly decreased from 52.1 mm<sup>3</sup> to 15.4 mm<sup>3</sup> and from 50.8 mm<sup>3</sup> to 18.6 mm<sup>3</sup>, respectively (Figure 2). Adhesions were observed in the control group animals (3.1  $\pm$  0.9), while no adhesion was detected in reference drug (0.0  $\pm$  0.0,  $p$  < 0.001) and HrHp oil-treated groups (0.0  $\pm$  0.0,  $p$  < 0.001) at the end of the experiment (Table 1). After the second laparotomy, regular estrous cycles were detected only in the reference drug and HrHp oil-treated group animals after the 10<sup>th</sup> post-treatment day.

Pretreatment and post-treatment TNF- $\alpha$ , VEGF and IL-6 levels in peritoneal fluid were determined to be significantly different in HrHp oil treatment group and reference group when compared to control group. The levels of TNF- $\alpha$  decreased from 7.02  $\pm$  1.33 pg/mL to 4.78  $\pm$  1.02 pg/mL ( $p$  < 0.01); VEGF from 17.39  $\pm$  8.52 pg/mL to 9.67  $\pm$  5.04 pg/mL ( $p$  < 0.01); and IL-6 from 50.95  $\pm$  22.84 pg/mL to 29.11  $\pm$  7.45 pg/mL ( $p$  < 0.01) after HrHp oil treatment (Table 2).

In the histopathological examination of tissue sections, endometriotic lesions were observed in all experimental groups with

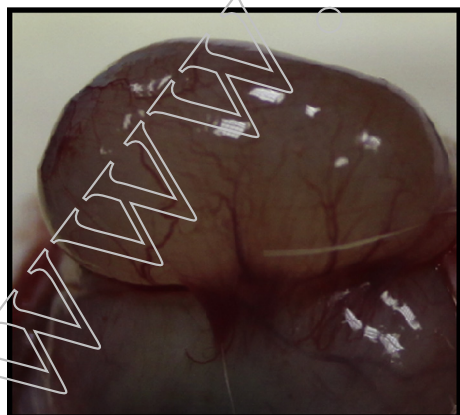


Figure 1. Appearance of cystic formation after the second laparotomy.

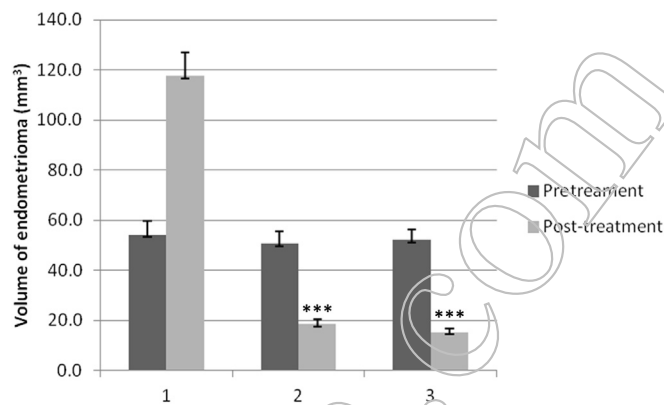


Figure 2. Comparison of the pretreatment and the post-treatment endometriotic implant volumes. 1: control; 2: HrHp oil; 3: buserelin acetate. Data are mean  $\pm$  standard deviation; \*\*\*  $p$  < 0.001. HrHp oil = mixture of sea buckthorn and St. John's wort oils.

Table 1

Intra-abdominal adhesion scores of the endometriotic implants.

Material	Adhesion scores	
	Pretreatment	Post-treatment
Control	2.7 $\pm$ 0.5	3.1 $\pm$ 0.9
HrHp oil	2.5 $\pm$ 0.4	0.0 $\pm$ 0.0***
Buserelin acetate	2.6 $\pm$ 0.6	0.0 $\pm$ 0.0***

Data are presented as mean  $\pm$  standard deviation.

\*\*\*  $p$  < 0.001.

HrHp oil = mixture of sea buckthorn and St. John's wort oils.

different degrees and different characters. Superficially located simple implantations or profound invasions between the muscle fibers were seen in the animals. Invasive epithelial cell islands between the muscle fibers and also foreign body reaction were mostly seen in the control group and lesser in the HrHp oil-treated group and then in the reference drug treated group. By contrast, one or more encapsulated cyst-like structures lined by epithelial cells at their luminal surface were detected only in the reference drug treated group. However, abscessation of these cyst-like structures were circularly arranged by a neovascularized granulation tissue from the bottom and generally contain inflammatory cells and hemosiderin filled macrophages. The most aggressive endometriotic lesions were detected in the control group and then the HrHp oil-treated and reference drug groups (Figure 3).

### Discussion

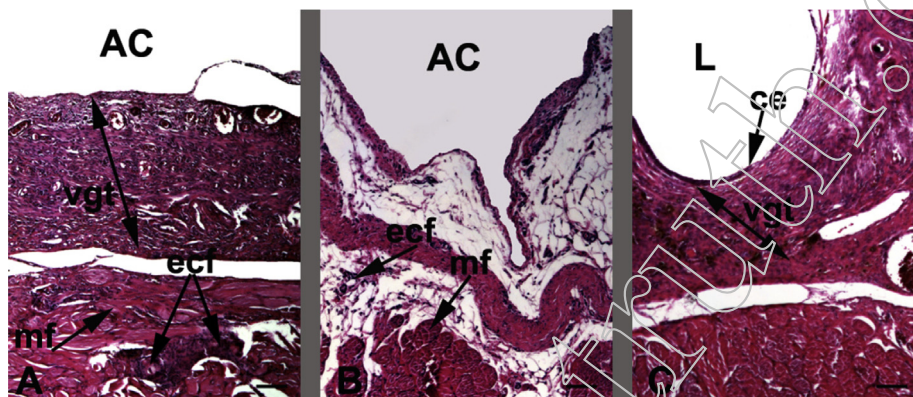
Endometriosis, a chronic gynecological disease, usually starts with the adhesion of endometrial cells to the peritoneal membrane, which causes an inflammatory response [23]. Previous reports have alleged that the inflammatory cytokines such as IL-1, IL-6, IL-8, IL-18, and TNF- $\alpha$  may have a role in the pathogenesis of endometriosis [18,24,25]. During the peritoneal implantation of the endometrium, VEGF, a potent angiogenic factor, possesses an important role in the development of endometriosis [23]. Therefore, in the present study, peritoneal TNF- $\alpha$ , VEGF, and IL-6 levels of the experimental animals were also analyzed. Pre- and post-treatment values of TNF- $\alpha$ , VEGF, and IL-6 levels were found to be significantly reduced in HrHp oil and reference drug treated groups. The levels of TNF- $\alpha$ , VEGF, and IL-6 decreased by 30.1%, 57.5%, and 42.9% in the HrHp oil-treated group; and 47.4%, 66.8%, and 53.6% in the reference drug-treated group, respectively, when compared with the control group levels

**Table 2**Peritoneal tumor necrosis factor (TNF)- $\alpha$ , vascular endothelial growth factor (VEGF), and interleukin (IL)-6 levels before and after treatment in all groups.

Material	Peritoneal TNF- $\alpha$ level (pg/mL)			Peritoneal VEGF level (pg/mL)			Peritoneal IL-6 level (pg/mL)		
	Pretreatment	Post-treatment	%	Pretreatment	Post-treatment	%	Pretreatment	Post-treatment	%
Control	6.64 $\pm$ 1.45	7.14 $\pm$ 1.36	—	19.25 $\pm$ 7.54	22.73 $\pm$ 9.81	—	54.17 $\pm$ 19.75	47.62 $\pm$ 16.83	—
HrHp oil	7.02 $\pm$ 1.33	4.78 $\pm$ 1.02**	30.1	17.39 $\pm$ 8.52	9.67 $\pm$ 5.04**	57.45	50.95 $\pm$ 22.84	29.11 $\pm$ 7.45**	42.9
Buserelin acetate	6.17 $\pm$ 1.28	3.75 $\pm$ 0.63***	47.4	18.07 $\pm$ 6.23	7.54 $\pm$ 3.11***	66.8	52.05 $\pm$ 19.49	22.08 $\pm$ 6.20***	53.6

Data are presented as the mean  $\pm$  standard deviation.\*\*  $p < 0.01$ ; \*\*\*  $p < 0.001$ .

HrHp oil = mixture of sea buckthorn and St. John's wort oils.



**Figure 3.** Histology of the tissue samples of experimental group animals. (A) Control group; neovascularized granulation tissue and profound invasion of epithelial cells between the muscle fibers, original magnification was  $\times 4$  and the scale bars represent 100  $\mu$ m, hematoxylin–eosin (HE). (B) HrHp oil administered group; superficial invasion of epithelial cells, original magnification was  $\times 4$  and the scale bars represent 100  $\mu$ m, HE. (C) Buserelin acetate group; a cyst-like structure, neovascularized granulation tissue, original magnification was  $\times 4$  and the scale bars represent 100  $\mu$ m, HE. AC = abdominal cavity; ce = cyst epithelium; ecf = epithelial cell folds; HrHp oil = mixture of sea buckthorn and St. John's wort oils; L = lumen; mf = muscle fibers; vgt = neovascularized granulation tissue.

(Table 2). The comparatively lower levels of TNF- $\alpha$ , VEGF, and IL-6 in HrHp oil-treated group, might possibly be due to the regression of angiogenesis and endometrial implants [4].

The oil obtained from berries of *H. rhamnoides* is used in folk medicine for the treatment of erosion of the uterus and genital inflammations [10]. It has been reported that oral intake of sea buckthorn oil exerted beneficial effects on vaginal health clinically. Results of two placebo-controlled, randomized, double-blind clinical studies in women suffering either Sjögren's syndrome or postmenopausal symptoms have demonstrated that sea buckthorn oil relieved the complaints due to dryness of genital mucous membranes [26,27].

In previous phytochemical studies on *H. rhamnoides* berries; carotenoids, sterols, tocopherols and tocotrienols, triterpenols, isoprenols, flavonoids, anthocyanidins, and organic acids were reported as the main ingredients [13,14]. The lipid-soluble components such as carotenoids, sterols, tocopherols, etc. may be postulated as the components responsible for such effect. A multicenter case–control study has also supported the favorable role of dietary carotenoids on the risk of endometrial cancer development [28].

Traditional use of *H. perforatum* against endocrine disorders including endometritis has been documented by the Committee on Herbal Medicinal Products [15]. In a previous study, hypericin and its derivatives were reported to be the main active ingredients of the oily extract of *H. perforatum* for wound healing [16]. Hypericin was also shown to act against human endometrial cancer cells. It was demonstrated that treatment of endometrial cancer cells with both 5-aminolevulinic acid and hypericin followed by illumination induced a significantly higher phototoxicity as assessed by reduced colony formation [29]. By contrast, antiangiogenic treatment strategies have recently held great promise as an important component of future endometriosis therapy [30]. The essential components in

hypericin and hyperforin were experimentally (*in vivo* and *in vitro*) shown to exert remarkable antiangiogenic activity [31,32].

In the present study, the potential effect of HrHp oil formulation in the treatment of endometriosis was investigated in a rat surgical model. According to the results, HrHp oil formulation was found to be active as much as the reference drug (buserelin acetate) in the treatment of endometriosis by regressing the production of inflammatory cytokines as well as VEGF and the activity could possibly be attributed to its carotenoid, sterol, and hypericin contents.

### Conflicts of interest

The authors have no conflicts of interest relevant to this article.

### References

- [1] Taylor R, Lebovic DI. Endometriosis. In: Strauss JF, Barbieri RL, editors. Yen & Jaffe's reproductive endocrinology. 7th ed. Philadelphia: Elsevier Publication; 2014. p. 565–85.
- [2] Anaf V, Simon P, El Nakadi I, Fayt I, Simonart T, Buxant F, et al. Hyperalgesia, nerve infiltration and nerve growth factor expression in deep adenomyotic nodules, peritoneal and ovarian endometriosis. Hum Reprod 2002;17: 1895–900.
- [3] Olive DL, Pritts AE. Treatment of endometriosis. New Engl J Med 2001;345: 266–75.
- [4] Neto NJ, Coelho TM, Aguiar GC, Carvalho LR, de Araújo AG, Girão MJ, et al. Experimental endometriosis reduction in rats treated with *Uncaria tomentosa* (Cat's claw) extract. Eur J Obstet Gynecol Reprod Biol 2011;154:205–8.
- [5] Stephens L, Whitehouse J, Polley M. Western herbal medicine, epigenetics, and endometriosis. J Altern Complement Med 2013;19:853–9.
- [6] Yang B, Kallio H. Supercritical CO<sub>2</sub>-extracted sea buckthorn (*Hippophae rhamnoides*) oils as new food ingredients for cardiovascular health. In: Proceedings of Health Ingredients of Europe, Paris; 2002, p. 17–19.
- [7] Kallio H, Yang B, Peippo P. Effects of different origins and harvesting time on vitamin C, tocopherols and tocotrienols in sea buckthorn (*Hippophae rhamnoides* L.) berries. J Agric Food Chem 2002;50:6136–42.

- [8] Suryakumar G, Gupta A. Medicinal and therapeutic potential of sea buckthorn (*Hippophae rhamnoides* L.). *J Ethnopharmacol* 2011;138:268–78.
- [9] Süleyman Z, Erdemoğlu N, Küsmenoğlu Ş, Gürbüz İ, Yesilada E, Çalış İ. Fatty acid composition and anti-ulcerogenic activity of *Hippophae rhamnoides* fruit oil. *J Fac Pharm Gazi Univ* 1998;15:11–7.
- [10] Li TSC, Wang LCH. Physiological components and health effects of ginseng, echinacea and sea buckthorn. In: Mazza G, editor. *Functional foods, biochemical and processing aspects*. Lancaster, PA: Technomic Publishing Company; 1998. p. 329–56.
- [11] Yesilada E, Honda G, Sezik E, Tabata M, Goto K, Ikeshiro Y. Traditional medicine in Turkey IV. Folk medicine in the Mediterranean subdivision. *J Ethnopharmacol* 1993;39:31–8.
- [12] Yesilada E, Honda G, Sezik E, Tabata M, Fujita T, Tanaka T, et al. Traditional medicine in Turkey. V. Folk medicine in the inner Taurus Mountains. *J Ethnopharmacol* 1995;46:133–52.
- [13] Bombardelli E, Morazzoni P. *Hypericum perforatum*. *Fitoterapia* 1995;66:43–68.
- [14] WHO Monographs-Herba Hyperici. WHO (World Health Organization) monographs on selected medicinal plants, vol. 2. Malta: WHO; 2002. p. 149–71.
- [15] European Medicine Agency. Assessment Report on *Hypericum perforatum* L., herba. Committee on herbal medicinal products, doc.ref: EMA/HMPC/101303/2008, London; November 12, 2009.
- [16] Süntar İP, Akkol EK, Yilmazer D, Baykal T, Kirmizibekmez H, Alper M, et al. Investigations on the *in vivo* wound healing potential of *Hypericum perforatum* L. *J Ethnopharmacol* 2010;127:468–77.
- [17] Vernon MW, Wilson EA. Studies on the surgical induction of endometriosis in the rat. *Fertil Steril* 1985;44:684–94.
- [18] Demirel MA, Süntar İ, İlhan M, Keles H, Kupeli Akkol E. Experimental endometriosis remission in rats treated with *Achillea biebersteinii* Afan.: histopathological evaluation and determination of cytokine levels. *Eur J Obstet Gyn R B* 2014;175:172–7.
- [19] Altıntaş D, Kokcu A, Tosun M, Cetinkaya MB, Kandemir B. Comparison of the effects of cetrorelix, a GnRH antagonist, and leuprolide, a GnRH agonist, on experimental endometriosis. *J Obstet Gynaecol Re* 2008;34:1014–9.
- [20] Blauer KL, Collins RL. The effect of intraperitoneal progesterone on post-operative adhesion formation in rabbits. *Fertil Steril* 1988;49:144–9.
- [21] Keenan JA, William-Boyce PK, Massey PJ, Chen TT, Caudle MR, Bukovsky A. Regression of endometrial explants in a rat model of endometriosis treated with the immune modulators loxoribine and levamisole. *Fertil Steril* 1999;72:135–41.
- [22] Katsuki Y, Takano Y, Futamura Y, Shibutani Y, Aoki D, Udagawa Y, et al. Effects of dienogest, a synthetic steroid, on experimental endometriosis in rats. *Eur J Endocrinol* 1998;138:216–26.
- [23] Kahraman İ. Anjiyogenezis inhibitörlerinin rat modelinde endometrial implantlar ve peritoneal sıvı vasküler endotelial büyüme faktörü üzerine etkileri [Ph.D. Thesis]. Ankara: University of Baskent; 2008.
- [24] Kondo W, Andreatza dal Lago E, Noronha LD, Olandoski M, Kotze PC, Ferreira do Amaral V. Effect of anti-TNF- $\alpha$  on peritoneal endometrial implants of rats. *Rev Col Bras Cir* 2011;38:266–72.
- [25] Lebovic DI, Mueller MD, Taylor RN. Immunobiology of endometriosis. *Fertil Steril* 2001;75:1–10.
- [26] Yang B, Erkkola R. Sea buckthorn oils, mucous membranes and Sjögren's syndrome with special reference to latest studies. In: Singh V, Kallio H, Yang B, Mörsel T, Sawhney RC, Bala M, et al., editors. *Seabuckthorn (Hippophae L.), a multipurpose wonder plant. Advances in research and development*, vol. III. New Delhi: Dya Publishing House; 2008. p. 254–67.
- [27] Larmo PS, Yang B, Hyssala J, Kallio HP, Erkkola R. Effects of sea buckthorn oil intake on vaginal atrophy in postmenopausal women: a randomized, double blind, placebo-controlled study. *Maturitas* 2014;79:316–21.
- [28] Pelucchi C, Dal Maso L, Montella M, Parpinel M, Negri E, Talamini R, et al. Dietary intake of carotenoids and retinol and endometrial cancer risk in an Italian case-control study. *Cancer Cause Control* 2008;19:1209–15.
- [29] Schneider-Yin X, Kurmanaviciene A, Roth M, Roos M, Fedier A, Minder EI, et al. Hypericin and 5-aminolevulinic acid-induced protoporphyrin IX induce enhanced phototoxicity in human endometrial cancer cells with non-coherent white light. *Photodiagn Photodyn* 2009;6:12–8.
- [30] Laschke MW, Menger MD. Anti-angiogenic treatment strategies for the therapy of endometriosis. *Hum Reprod Update* 2012;18:682–702.
- [31] Martínez-Poveda B, Quesada AR, Medina MA. Hyperforin, a bioactive compound of St. John's wort, is a new inhibitor of angiogenesis targeting several key steps of the process. *Int J Cancer* 2005;117:775–80.
- [32] Yee KK, Soo KC, Olivo M. Anti-angiogenic effects of hypericin-photodynamic therapy in combination with Celebrex in the treatment of human nasopharyngeal carcinoma. *Int J Mol Med* 2005;16:993–1002.