

Clinical effect of hydrocolloid dressings in prevention and treatment of infant diaper rash

XIAO-PING QIAO¹ and YAN-ZHEN GE²

Departments of ¹Traditional Chinese Medicine and ²Pediatrics,
Liaocheng People's Hospital, Liaocheng, Shandong 252000, P.R. China

Received June 6, 2016; Accepted September 16, 2016

DOI: 10.3892/etm.2016.3848

Abstract. The aim of the study was to investigate the application of hydrocolloid dressings in the prevention and treatment of infant diaper rash. A total of 210 infants with diaper rash were included in the study and randomized into 3 groups of 70 infants. Infants in group A received hydrocolloid dressings and individualized nursing; infants in group B received mupirocin plaster and topical application of pearl powder as well as routine nursing; and infants in group C received zinc oxide plaster and routine nursing. The clinical efficacy, incidence of adverse events, time to resolution of diaper rash, hospitalization duration, mean cost and satisfaction of nursing were compared between the 3 groups. After 1 cycle of treatment and nursing, the difference in the healing rate of mild diaper rash between groups A, B and C was significant ($P < 0.05$), with the best healing rate in group A. Differences in the healing rate of grade I and II diaper rash between groups A, B and C was significant ($P < 0.05$), with the best healing rate in group A. The incidence of adverse events in infants between groups A, B and C were significantly different ($P < 0.05$), with the lowest incidence in group A (2.9%). The time to resolution of diaper rash, hospitalization duration and cost in infants were not significantly different ($P < 0.05$). The satisfaction rate of nursing for the parents of groups A, B and C was 98.6, 87.1 and 80.0%, respectively ($P < 0.05$). Hydrocolloid dressings combined with individualized nursing may prevent and treat infant diaper rash effectively, decrease the incidence of adverse reactions significantly, shorten time to resolution of diaper rash and hospitalization duration, reduce mean hospitalization cost, improve parent satisfaction and promote nursing-patient harmony. Thus, this method of treatment was worthy of clinical application.

Introduction

Moist diaper with urine and stool may irritate the buttock skin around the diaper, cause diaper rash, redness and hyperemia in the skin of buttock and perineum, erythema and papules, even excoriation and erosion (1). Infants with diaper rash may be crying, agitated and sleepless due to redness in the diaper area. Prophylactics are important in the clinical management of infant diaper rash. Parents should pay attention to the redness around the buttock of the infant and provide immediate treatment (2,3).

In the present study, we selected 210 infants who received hydrocolloid dressings, mupirocin plaster as well as topical application of pearl powder and zinc oxide plaster for diaper rash, and underwent nursing intervention from January, 2015 to December, 2015. The results of the present study showed that hydrocolloid dressings combined with individualized nursing may prevent and treat infant diaper rash effectively, decrease the incidence of adverse reactions significantly, shorten time to resolution of diaper rash and hospitalization duration, reduce mean hospitalization cost, improve parent satisfaction and promote nursing-patient harmony. Therefore, this method of treatment was worthy of clinical application.

Materials and methods

General. A total of 210 infants who met the diagnostic criteria of diaper rash, were included in the present study from January, 2015 to December, 2015. A total of 106 males and 104 females, with a mean age of 5.7 ± 1.2 months (3-12 months), and disease course of 16.4 ± 2.5 days (2-25 days) were included. Of the 210 cases, there were 82 mild cases, 75 severity grade I cases and 53 severity grade II cases. Admission diagnosis included: 30 infants with neonatal diarrhea, 15 infants with neonatal hyperbilirubinemia, 15 premature infants, 3 infants with neonatal hypoxic-ischemic encephalopathy, 3 infants with infective pneumonia, 2 infants with hyaline membrane disease and 2 infants with intracranial hemorrhage. The differences in gender, age, disease course and condition among these infants were not significant.

Approval for the study was obtained from the Ethics Committee of the Liaocheng People's Hospital. Informed consent of patients and relatives was obtained prior to inclusion in the study.

Correspondence to: Dr Yan-Zhen Ge, Department of Pediatrics, Liaocheng People's Hospital, 67 West Dongchang Road, Liaocheng, Shandong 252000, P.R. China
E-mail: x63195901taoqianw@163.com

Key words: hydrocolloid dressings, pediatrics, diaper rash, individualized nursing

Treatments. The infants in group A received hydrocolloid dressings [State Food and Drug Administration (import) 3640809, 2013; Coloplast A/S, Humlebæk, Denmark] with a cycle of 5 days. Hydrocolloid dressings (10x10 cm) was cut as Fig. 1, with a left/right margin of 3 cm and an upper margin of 2.5 cm. The prepared hydrocolloid dressings were gently applied and fixed on the redness of the affected buttock. The hydrocolloid dressings were changed based on the actual use. The hydrocolloid dressings were immediately changed in the case of ivory-white bubble or stool/urine on hydrocolloid dressings.

The infants in group B received mupirocin plaster (SFDA approval no. H10930064, a cycle of 5 days; American Tianjin Smith Kline Pharmaceutical Co., Ltd., Tianjin, China), and topical application of pearl powder (SFDA approval no. Z51020812; Sichuan Kelun Pharmaceutical Co., Ltd., Sichuan, China).

The infants in group C received zinc oxide plaster (SFDA approval no. H11022229; Beijing Shuangji Pharmaceutical Co., Ltd., Beijing, China).

Nursing measures. Individualized nursing was provided in group A: i) The buttock was cleaned with warm water after defecation and dried with gauze, and the diaper was changed timely. ii) The trauma was disinfected with iodophor, cleaned with normal saline, and dried with a dry towel. Hydrocolloid dressings film was pasted on the trauma. The nurse avoided direct contact with the inner side of hydrocolloid dressings film via hands, and ensure no air bubbles between the film and skin, leaving plain and closed interface between the film and skin. The hydrocolloid dressings film were immediately changed in the cases of fluid or feces/urine. The hydrocolloid dressings film was very gently removed to ensure no damage occurred to the delicate skin. iii) The induction of diaper rash was prevented to ensure clean and dry buttock skin (4). iv) The nurse changed the diaper timely, cleaned the buttock with warm water after defecation (soap was prohibited) and dried gently with a towel to prevent skin injury. v) Baby powder was not recommended during treatment, while paper diaper with good air permeability or soft cotton diaper was recommended, albeit plastic diaper or rubber diaper was prohibited. vi) When ulcerate or erosion occurred in buttock skin, sterile gauze was applied on the trauma, the frequency of changing sterile gauze was dependent on the actual condition of trauma. vii) Appropriate temperature and humidity was maintained to avoid low room temperature, which would impact the healing and recovery of trauma. viii) The nurse was required to educate the child's parents regarding the diaper rash, explain any problems patiently, communicate with parents, provide psychological intervention and ease negative sentiment.

Observational measurements. The clinical healing, incidence of adverse events, time to resolution of diaper rash, hospitalization duration, mean cost and satisfaction of nursing were compared between the 3 groups.

Statistical analysis. SPSS 20.0 software (IBM SPSS, Armonk, NY, USA) was used for statistical analysis. Measurement data were presented as mean \pm standard deviation and analyzed by t-test. Enumeration data were presented as cases and analyzed

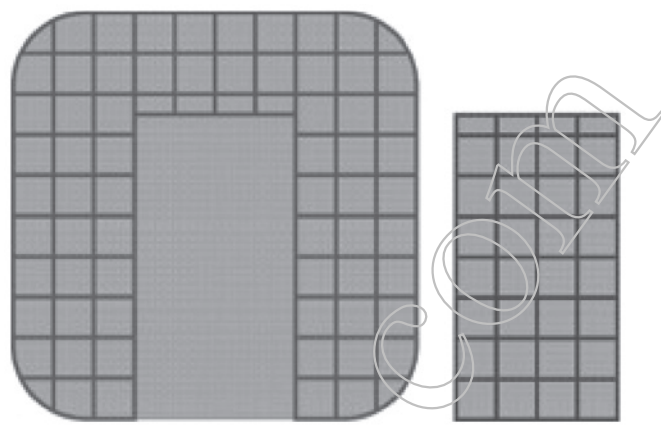


Figure 1. Schematic diagram for the cutting of hydrocolloid dressings.

using the Chi-square test. Non-parametric data were analyzed by the rank-sum test, and multi-samples were analyzed using ANOVA. $P < 0.05$ was considered to indicate a statistically significant difference.

Results

Healing rate. After 1 cycle of treatment and nursing, the healing rate of diaper rash in infants between groups A, B and C was significantly different ($P < 0.05$), with the highest healing rate in group A (96.3%). As shown in Table I, the healing rate of severity grade I diaper rash in infants between groups A, B and C was significantly different ($P < 0.05$), with highest healing rate in group A (92.0%). The healing rate of severity grade II diaper rash in infants between groups A, B and C was significantly different ($P < 0.05$), with the highest healing rate in group A (72.2%). Classical severity grade I cases: one child was diagnosed as severity grade I before treatment (Fig. 2A), 24 h after treatment, the symptoms were relieved (Fig. 2B), and 5 days after treatment, the child recovered (Fig. 2C).

Factors. After treatment and nursing, the incidence of adverse events in infants between groups A, B and C was significantly different ($P < 0.05$), with the lowest incidence in group A (2.9%) (Table II). As shown in Table III, after treatment and nursing, the time to resolution of diaper rash, hospitalization duration and cost in infants were not significantly different ($P < 0.05$), with the shortest time to resolution of diaper rash and hospitalization duration as well as lowest mean hospitalization cost in group A. The satisfaction rate of nursing for the parents of groups A, B and C was 98.6, 87.1 and 80.0%, respectively, and the difference was significant ($P < 0.05$; Table IV).

Discussion

Diaper rash in infants is also known as red buttock, and was a common disease of skin injury in infants (5). The induction factors of diaper rash include: i) Infant skin was delicate, if the diaper had not been changed immediately, the urea in urine were metabolized into ammonia, which may irritate infant buttock skin and cause inflammation. ii) The moist and warm diaper region of infants was susceptible to maceration

Table I. The healing of infants after 1 cycle.

Groups	No.	Mild		Severity grade I			Severity grade II			
		No.	Healing rate (%)	No.	Healing	Healing rate (%)	No.	Healing	Healing rate (%)	
A	70	27	26	96.3	25	23	92.0	18	13	72.2
B	70	27	22	81.5	25	18	72.0	18	9	50.0
C	70	28	20	71.4	25	15	60.0	17	6	35.3
P-value			<0.05			<0.05			<0.05	

Table II. The incidence of adverse events in infants.

Groups	No.	Skin allergies	Pustule	Itching	Yellow exudate	Incidence of adverse events (%)	P-value
A	70	0	1	1	0	2.9	<0.05
B	70	1	2	2	1	8.6	<0.05
C	70	1	4	2	1	11.4	<0.05

Table III. Time to resolution of diaper rash, hospitalization duration and cost in infants (mean \pm standard deviation).

Groups	No.	Time to resolution (h)	Hospitalization duration (day)	Hospitalization cost (RMB)
A	70	71.64 \pm 16.72	5.4 \pm 1.3	2564.7 \pm 367.2
B	70	86.81 \pm 18.43	7.1 \pm 2.2	3637.5 \pm 412.8
C	70	107.53 \pm 21.43	9.6 \pm 2.7	4484.6 \pm 533.4
P-value		<0.05	<0.05	<0.05

Table IV. Satisfaction rate of nursing in parents.

Groups	No.	Very satisfied	Satisfied	Dissatisfied	Total satisfaction (%)	P-value
A	70	41	28	1	98.6	<0.05
B	70	34	27	9	87.1	<0.05
C	70	29	27	14	80.0	<0.05

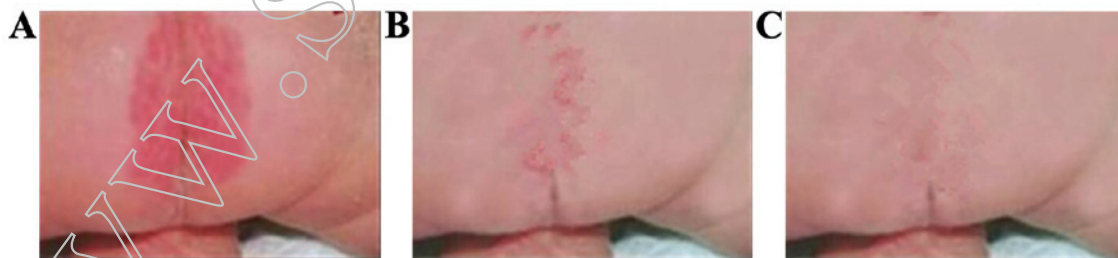

Figure 2. Images of an infant (severity grade I) pre- and post-treatment. (A) The symptoms of an infant (severity grade I) in group A before treatment; (B) the relieved symptoms of an infant (severity grade I) in group A 24 h after treatment; and (C) the healing of an infant (severity grade I) in Group A 5 days after treatment.

of stratum corneum, leading to gradual degeneration of the barrier function of epidermis, and as a result, fungi penetrated the skin and caused fungal infection. iii) Infant was of poor immunity and susceptible to diseases, thus the administra-

tion of antibiotics may have caused secondary infection, and prototype antibiotics were excreted with feces and urine. Consequently, flora imbalance occurred in the skin and feces in the diaper region, leading to diaper rash (6-9).

Investigators have reported the incidence of diaper rash at 16-40%, therefore, more attention should be paid to the prevention and treatment of diaper rash (10-12). Currently, there are many available medications for infant diaper rash with varying efficacy. Zinc oxide plaster can repair and protect skin tissues. However, zinc oxide plaster has some antibacterial effects, but is slow and inconvenient for topical application (13). Mupirocin plaster is a topical antibiotic plaster, and low levels of mupirocin had a bacteriostatic effect and a high level of mupirocin had bactericidal effect. With a broad antimicrobial spectrum, mupirocin is efficacious for gram-positive and -negative bacteria (14). Pearl powder has heat-clearing and detoxifying effects, and an astringent effect on tissue regeneration. Mupirocin plaster combined with pearl powder may form a protective membrane on human skin surface, thus may prevent the irritation of urine and inhibit bacterial growth.

Active components of hydrocolloid dressings include sodium carboxymethyl cellulose particles, medical tape and calcium alginate, and its absorptive capacity has been demonstrated previously (15). With good self-adhesion and permeability, hydrocolloid dressings are also convenient in clinical application. Additionally, hydrocolloid dressings are closed, which can preserve the release of biologically active substances and form low oxygen tension on the surface and stimulate the release of interleukins, enhance the bactericidal effect locally as well as repair and protect damaged skin. Hydrocolloid dressings allow for the penetration of oxygen and water into skin while permitting cleaning, drying and moisturizing effects on human skin (16). Hydrocolloid dressings have been of great interest and extensively applied. However, clinical application of hydrocolloid dressings in the treatment of diaper rash was limited currently.

The present study included 210 infants with diaper rash who underwent different therapeutic options, and explored the application of hydrocolloid dressings in the treatment of diaper rash. The results demonstrated the clinical efficacy, incidence of adverse events, time to resolution of diaper rash, hospitalization duration and mean hospitalization cost. The best efficacy, lowest incidence of adverse events, shortest time to resolution of diaper rash and hospitalization duration as well as lowest mean hospitalization cost were observed in the group with hydrocolloid dressings. Therefore, the efficacy of hydrocolloid dressings in the treatment of diaper rash was better than mupirocin plaster and pearl powder combined with zinc oxide plaster.

Infant diaper rash, especially neonatal diaper rash, may cause pain of infants and increase the burden of nurses. Nursing should be enhanced for infant diaper rash, otherwise, it would cause damage or delay healing time, or even induce secondary infection or erosion (17,18). However, the clinical nursing of infant diaper rash is difficult. Jing and Xia (19) used moist expose burn ointment to treat infant diaper rash and obtained good efficacy. Previous studies summarized the nursing of neonatal buttock erythema and suggested the importance of frequent cleaning and urination, pure cotton diapers and breast feeding (20,21).

In the present study, the nursing staff performed individualized nursing during the treatment of diaper rash with hydrocolloid dressings in group A. The results showed that the satisfaction rate of nursing in group A parents was significantly

better than those in groups B and C ($P < 0.05$). This result indicated that individualized nursing during the treatment with hydrocolloid dressings was able to relieve infant discomfort effectively, promote early recovery, improve nursing quality and achieve parent satisfaction.

Our experience indicated that improvement of nursing quality and skills, and innovation of nurses were beneficial to the clinical application of hydrocolloid dressings in the prevention and treatment of infant diaper rash. Individualized nursing, which was centered on patients, has been gaining interest recently. Individualized nursing requires higher quality of nursing staff and nursing skills. Thus, hospitals should provide more training for nursing skills, improve comprehensive quality of nursing skills, and improve nursing quality. Hospitals may conduct seminars on nursing skills periodically, encourage nurses to communicate experiences and share precautions and encourage parents to provide advice on clinical nursing. Nurse-patient harmony is crucial for individualized nursing. The parents of infants with diaper rash can be anxious or depressed and nurse-patient disharmony may cause medical disputes. Therefore, nurses should work in patient-oriented manner, explain the disease to parents patiently, relieve negative sentiment of parents, reduce unnecessary medical disputes and promote nurse-patient harmony (22).

In conclusion, it is crucial to identify the cause(s) for infant diaper rash, provide treatment and appropriate nursing measures, to prevent diaper rash from recurring. Hydrocolloid dressings, combined with individualized nursing, are an effective treatment for infant diaper rash and worthy of future clinical application.

References

1. Adib-Hajbaghery M, Mahmoudi M and Mashaieki M: Shampoo-clay heals diaper rash faster than calendula officinalis. *Nurs Midwifery Stud* 3: e14180-e14180, 2014.
2. Gaunder BN and Plummer E: Diaper rash: Managing and controlling a common problem in infants and toddlers. *J Pediatr Health Care* 1: 26-34, 1987.
3. Shimizu M, Sakai S, Tatekawa Y, Ishikawa S, Miyamoto M and Yachie A: An infant with PELVIS (perineal hemangioma, external genital malformations, lipomyelomeningocele, vesicorenal abnormalities, imperforate anus, and skin tag) syndrome misdiagnosed as diaper rash. *J Pediatr* 165: 634, 2014.
4. Umachitra G: Disposable baby diaper - a threat to the health and environment. *J Environ Sci Eng* 54: 447-452, 2012.
5. Mohamadi J, Motaghi M, Panahi J, Havasian MR, Delpisheh A, Azizian M and Pakzad I: Anti-fungal resistance in candida isolated from oral and diaper rash candidiasis in neonates. *Bioinformation* 10: 667-670, 2014.
6. Shin HT: Diagnosis and management of diaper dermatitis. *Pediatr Clin North Am* 61: 367-382, 2014.
7. Li CH, Zhu ZH and Dai YH: Diaper dermatitis: A survey of risk factors for children aged 1-24 months in China. *J Int Med Res* 40: 1752-1760, 2012.
8. Ratliff C and Dixon M: Treatment of incontinence-associated dermatitis (diaper rash) in a neonatal unit. *J Wound Ostomy Continence Nurs* 34: 158-161, discussion 161-162, 2007.
9. Mak SS, Molassiotis A, Wan WM, Lee IY and Chan ES: The effects of hydrocolloid dressing and gentian violet on radiation-induced moist desquamation wound healing. *Cancer Nurs* 23: 220-229, 2000.
10. Martin FT, O'Sullivan JB, Regan PJ, McCann J and Kelly JL: Hydrocolloid dressing in pediatric burns may decrease operative intervention rates. *J Pediatr Surg* 45: 600-605, 2010.
11. Block SL: Perianal dermatitis: Much more than just a diaper rash. *Pediatr Ann* 42: 12-14, 2013.
12. Levy M: Diaper rash syndrome or dermatitis. *Cutis* 67 (Suppl 5): 37-38, 2001.

13. Baldwin S, Odio MR, Haines SL, O'Connor RJ, Englehart JS and Lane AT: Skin benefits from continuous topical administration of a zinc oxide/petrolatum formulation by a novel disposable diaper. *J Eur Acad Dermatol Venereol* 15 (Suppl 1): 5-11, 2001.
14. Zhang Y: Clinical application of Mupirocin plaster in the treatment of pediatric diaper rash. *Shanxi J Med* 42: 269, 2013 (In Chinese).
15. Tan F, Wang K and Huang Z: The application of hydrocolloid dressings in the nursing of pressure sores. *Nurs J PLA* 28: 41-42, 2011.
16. Michel JM, Couilliet D, Bleicher R, Bloch B, Bochaton C and Groell S; Membres Du Groupe Plaies et Cicatrisation Des Hôpitaux Civils de Colmar: Hydrocolloid dressings. *Ann Dermatol Venereol* 129: 1326-1327, 2002 (In French).
17. Lohmann I: Guidelines for treatment and prevention of diaper rash. *Kinderkrankenschwester* 24: 481-482, 2005 (In German).
18. Ying L: Sesame oil in the treatment of infant diaper rash. *Nurs Res* 24: 567, 2010.
19. Jing L and Xia L: The treatment and nursing of 136 cases of infant buttock erythema. *Chinese J Misdiag* 10: 7235, 2010 (In Chinese).
20. Lin R: Clinical nursing of neonatal buttock erythema. *Adv Med* 5: 273, 2015 (In Chinese).
21. Wan H: The efficacy of Kanghuier transparent tape in severe neonatal buttock erythema. *Chinese J Prac Nurs* 31: 66, 2015 (In Chinese).
22. Yuan Y and Li X: The effect of delicate nursing in neonatal diaper rash. *Chinese Contemp Med* 21: 121-122, 2014 (In Chinese).

WWW.SCIENCE-TRUTH.COM